

# MICROPULSE P3 GLAUCOMA DEVICE REVOLUTIONIZES CYCLOPHOTOCOAGULATION

BY ROBERT J. NOECKER, MD, MBA

View the accompanying video for this case online at: [eye-tube.net/video/ITOPU](http://eye-tube.net/video/ITOPU).

The newly patented MicroPulse P3 (MP3) device (Iridex) provides the surgeon a very safe and efficacious solution to treating glaucoma utilizing Iridex's proprietary MicroPulse technology. While sharing similarities to G-Probe (Iridex), the primary advantage is the MP3 provides a kinder, gentler approach with identical efficacy yet improved safety profile.<sup>1</sup>

I have had the opportunity to be involved in the early work of this device and the more experience I have gained, the more I have been using the MP3 earlier in the glaucoma treatment algorithm. The MP3 device revolutionizes the current thinking of cyclophotocoagulation.

## EARLY WORK WITH MICROPULSE

MicroPulse technology finely controls thermal elevation by "chopping" a continuous-wave beam into an envelope of repetitive short pulses. For example, the surgeon uses G-Probe to perform transscleral cyclophotocoagulation, where focal burns are created in the ciliary body. The MP3 device, on the other hand, revolutionizes cyclophotocoagulation by using MicroPulse technology where the 31.3% duty cycle signifies that the laser is off 68.7% of the time, thereby avoiding focal heating and burning of the tissue. The technique of gliding the MP3 device back and forth over 1 hemisphere of the ciliary body results in a slow, steady application of laser energy (Figure 1).

Early work by Prof. Paul Chew, MBBS, MMed(Ophth), FRCSEd, FRCOphth, FAMS, of the National University of Singapore, demonstrated more than a 30% IOP reduction at 18 months.<sup>2</sup>

NUHS Prospective Clinical Study:<sup>2</sup>

- 33% IOP reduction at 18 months, N = 38 patients.
- Average meds reduced from 2.1 to 1.3.
- 73% success rate with 1.3 sessions.

## CASE PRESENTATION

An 80-year-old woman presented with pseudoexfoliation glaucoma. The patient was on maximally tolerated



medical therapy consisting of a prostaglandin analogue, a beta blocker, a carbonic anhydrase inhibitor, and an alpha-adrenergic agonist.

On examination, the intraocular pressure (IOP) measured 36 mm Hg in the patient's right eye and 18 mm Hg in her untreated left eye. Visual field loss in her right eye was significant. Thinning of the retinal nerve fiber layer and changes in the optic nerve of that eye were consistent with a diagnosis of moderate glaucoma.

Initial treatment with selective laser trabeculoplasty lowered the IOP in the patient's right eye to 32 mm Hg. Based on the glaucomatous damage already sustained, however, the target IOP was in the midteens.

---

*"I have found [the MicroPulse P3 device] provides a very safe and efficacious solution for IOP control. I have used it for some of my most complicated cases; however, I also feel comfortable using it for patients with earlier disease."*

---

## ADVANTAGES OF MP3 INSTEAD OF INVASIVE SURGERY

Traditional surgery such as trabeculectomy was an option in this case, however the patient would have faced problems with transportation back to the office for post-operative care. Moreover, the degree of IOP elevation and her age put the patient at high risk of developing choroidal effusion after filtration surgery. For these reasons, I recommended using the MP3 device to treat her glaucoma.

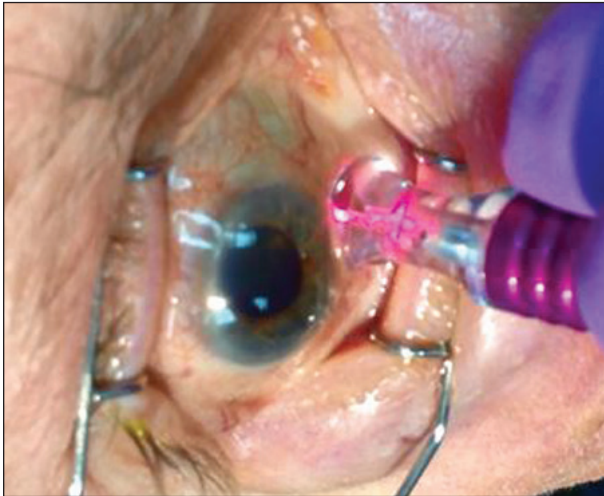


Figure 1. Application of the MicroPulse P3 technique.

**SURGICAL COURSE - OFFICE & OR COMPATIBLE**

I have used the MP3 device both in the office and the operating room. The patient in this case suffered from hypertension, cardiovascular disease, and was frail overall. I therefore decided to perform the procedure in the OR with the patient sedated and a peribulbar block in place.

The MicroPulse duty cycle on the laser was set to 31.3% and the power set to 2 W. Each half of the eye (superior and inferior) received a 90-second treatment. Specifically, I applied the MP3 device on her right eye directly posterior to the limbus and moved it over 6 clock hours every 10 seconds. The voice countdown timer feature on the laser makes this process very easy and efficient.

At the conclusion of surgery, 1% atropine was administered and an eye shield was placed. She received a prescription for difluprednate ophthalmic emulsion 0.5% (Durezol; Alcon) to be instilled 4 times daily.

**OUTCOME - NO PAIN DAY 1**

On postoperative day 1, the patient's IOP measured 10 mm Hg OD. Because she reported no pain, the atropine was discontinued as well as her glaucoma medications. I should note that not every patient has such a rapid, dramatic response.

The patient continued steroid therapy and returned for follow-up 1 week after surgery where her IOP measured 12 mm Hg. At 6 weeks, IOP was 14 mm Hg and 13 mm Hg at 3 months, and by this time steroid therapy had been tapered. At the 6-month postoperative visit, the patient's IOP measured 12 mm Hg (Table 1).

Preoperative	36 mm Hg, 3 Meds
Postoperative day 1	10 mm Hg
6-month follow-up	12 mm Hg, 0 Meds

**SAFETY PROFILE CREATES VERSATILE TREATMENT REGIMEN**

The MP3 device is a good option for patients in whom medical or previous laser therapy has lost effect over time and those whose response to previous laser therapy has been inadequate. The MP3 device can also be used as a primary treatment for elevated IOP. I consider the procedure for patients in whom a bleb is undesirable and those at increased risk of infection. I also may favor the MP3 device over traditional filtration surgery when a patient's response to the latter was poor in the fellow eye; the risk of the traditional filtration surgery's failing is high; or there is an increased risk of complications from traditional filtration surgery. In addition, I may recommend the MP3 device if I am worried about being able to remove sutures postoperatively. The procedure may also be preferred to traditional filtration surgery if the patient has a very high IOP or a history of vitrectomy or retinal surgery, and is more likely to experience hypotony maculopathy or choroidal effusions.

**PATIENT CASE SERIES**

I collected data on 50 consecutive patients with 6 months of follow-up after using the MP3 device (Table 2). The mean IOP in this group was 25.5 mm Hg (range, 15-50 mm Hg on 0-6 medications). On average, IOP decreased by 15.7 mm Hg (range, 0-50 mm Hg). None of my patients developed a pressure lower than 8 mm Hg long term. Ten patients required a retreatment to achieve their target IOP, which I felt comfortable performing given the attractive safety profile of the MP3 device.

N = 50
Mean pre-op IOP: 25.5 mm Hg
Mean 6 mos post-op IOP: 9.8 mm Hg
62% IOP reduction

**CONCLUSION**

Based on my experience with the MP3 device, I have found it provides a very safe and efficacious solution for IOP control. I have used it for some of my most complicated cases; however I also feel comfortable using it for patients with earlier disease in which we want to avoid a filtering bleb or the placement of hardware in the eye. ■

1. Aquino MCD. Micropulse versus continuous wave transscleral diode cyclophotocoagulation in refractory glaucoma: a randomized exploratory study. *Clin Experiment Ophthalmol.* 2015;43(1):40-46.  
 2. Tan A, Chockalingam M, Aquino M, Lim Z, et al. Micropulse transscleral diode laser cyclophotocoagulation in the treatment of refractory glaucoma. *Clin Experiment Ophthalmol.* 2010;38(3):266-72.

*Robert J. Noecker, MD, MBA, practices at Ophthalmic Consultants of Connecticut in Fairfield, and is an assistant clinical professor of ophthalmology at Yale University. He is a consultant to Iridex. Dr. Noecker may be reached at (203) 366-8000; noeckerrj@gmail.com.*

